

Trial of “Leonardo” a new rapid palatal expansion screw

Dr. Gabriele Galassini* Dr. Elena Marcuzzi ** Dr. Natasa Paulina***

Rapid palatal expansion has been a well-established procedure in orthodontic practice for many years now.

The first expansion was performed in 1860 by Emerson C. Angell, who, in San Francisco, expanded the maxillary arch of a fourteen and a half year old girl by a quarter of an inch in two weeks and noted the creation of an interincisal diastema, a sign that the expansion of the palatal suture had occurred.

This expansion was published in Dental Cosmos San Francisco Medical Press in 1860.

Different types of screws and activation protocols have been developed over the years. In the following project, we tested an innovative screw named **Leonardo** and made by **SIA Orthodontic Manufacturer (Italy)**, the characteristics of which allow for safe and effective activation, the

quantity of which can be easily controlled.

External examination of the screw (Fig. 1a – 1b).

- Compact in appearance (7.5 × 12 millimeters) with rounded edges and a very smooth structure.
- The small screw cylinder has four teeth for preventing return.
- Small casing to prevent the screw from unwinding.
- Notches for controlling the amount of activation: each notch corresponds to 2 mm of activation.
- Stopping pins which firmly block the [Expander] once opened.

This device prevents complete separation of the screw, with its subsequent disconnection and accidental opening of the two parts of the Expander.

Bench testing (Fig. 2a – 2b)

The opening of the screw with the special key was tested. The direction of activation is clearly indicated with a very visible arrow printed on the body of the Expander. The screw is activated by turning the key as far as it will go. At the end of each activation a loud click sound is heard, which is made when it meets the braking ring, provided with the device. The [braking ring] prevents the screw from unwinding when the activation screw is removed. This ensures the screw has been activated correctly and allows for the simple reinsertion of the key at the next activation, leaving the insertion hole perfectly accessible. There are notches for controlling how much the Expander is activated. The first two notches are stamped onto the body of the Expander; whilst the others are stamped on the concentric sliding guides. The latter notches are therefore visible during activation whilst the screw is opening. The notches are posi-



Figure 1a



Figure 2a Screw activated at 4mm




Figure 1b

Figure 2b Screw activated at 8mm - note the stopping device

tioned two millimeters apart from each other. Each activation moves the screw forward by 0.2 mm, corresponding to a ¼ turn of the total circumference of the screw. The screw is therefore particularly stable for the whole expansion process and this is thanks to the double concentric sliding guide, one of the peculiarities of this Expander. The Expander remains stable until its maximum opening limit is reached, at which point it blocks without disconnecting the screw itself, thanks to a solid stopping device. This means it is possible to take advantage of the full length of the screw in absolute safety.

Clinical test (Fig. 3a – 3b – 3c – 3d – 3e)

We tested the Expander on a five years old Patient with a left-sided cross-bite. We wanted to choose a very young Patient with a very small palate, given that it is mainly in these Patients that difficulties are most frequently encountered when activating the screws. These difficulties are linked to the confined spaces available for operating in. As a result, almost always, when the Parent removes the key after activating the screw, he/she tend to bring the screw back again, reducing how much they have activated it by. As a result, it is difficult for the Clinician to evaluate the real amount of expansion.

Activation protocol

The Expander was bonded to two bands and cemented onto the second deciduous molars and the rapid expansion protocol was implemented, which provides for the activation of the screw twice a day. (Fig. 4a – 4b)

We asked the Parents to do this themselves, but remained contactable at all times for anything they needed or in case of emergency. The Patient was examined after one week:

Rapid palatal expansion has been a well-established procedure in orthodontic practice for many years now.



Figure 3a

The Parents reported that they had noted the creation of an inter-incisive diastema on the fifth day, as is generally the case at this age, from our experience.

We discharged the Patient after having personally activated the screw to check its stability and the efficacy of the stopping device.

On the fourteenth day we terminated activation as the pre-determined amount of expansion of 5.5 millimeters had been reached (fig. 5a – 5b). The correct amount of activation was confirmed by the reference notches. As you can see from the photo, the third notch is about to appear, indicating six millimeters, but is still slightly hidden by the sliding guide, whilst the two previous notches are clearly visible on the body of the expander.

The expander remained blocked in the mouth for one month and was then replaced with a Quad helix (Fig. 6), which includes a marker for lingual repositioning.

The Quad helix remained in the mouth for another four months, after which no other type of restraint was required. This protocol provides for the replacement of the rapid expander with a Quad helix one month after the end of activation. It is a protocol we have been using for more than twenty years and has been tested on more than a hundred cases, proving to be particularly effective and free of any contraindications. In fact in our opinion, one month is more than enough for the consolidation of the midpalatal suture, given that this is the average time required for the consolidation of fractures. The replacement of the expander with a Quad helix provided with a lingual marker offers the following advantages: it reduces the encumbrance to the palate. In fact, often owing to its encumbrance, the rapid expander forces

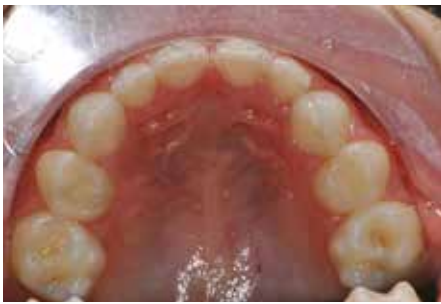

Figure 3b

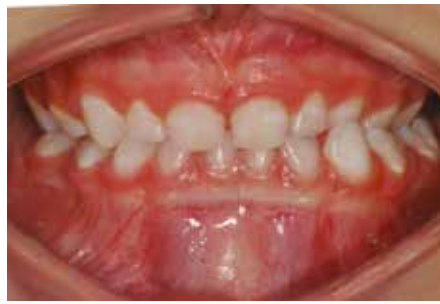

Figure 3d

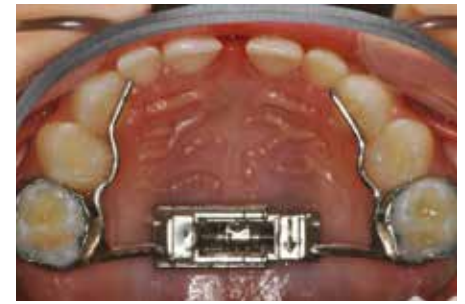

Figure 5a

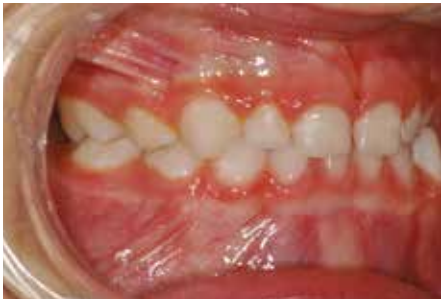

Figure 3c

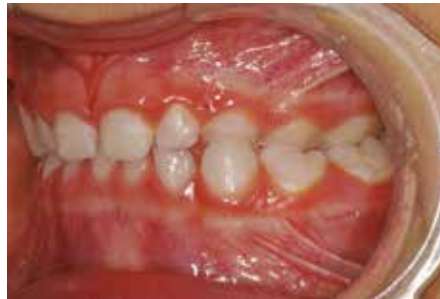

Figure 3e

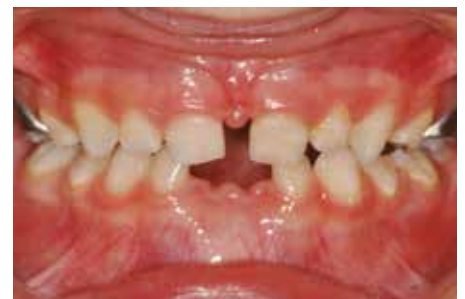

Figure 5b On the fourteenth day we terminated activation as the pre-determined expansion level of 5.5 millimeters had been reached

the tongue into a low, forward position, with a subsequent open bite from lingual dysfunction. As well as maintaining the breadth obtained with the rapid expander, the Quad helix can also increase it, by activating it by the required amount. Thanks to the lingual marker together with the modest encumbrance to the palate offered by the Quad helix (note its modeling in the photo), myofunctional re-education can be initiated immediately. This is definitely more important, in terms of the stability of the expansion and the prolonged use of the expander as a maintenance guard, given that the

same prevents correct lingual repositioning, an indispensable condition for the stability of our treatment in the long term. In addition, since it is an elastic device, the Quad helix does not block the two hemimaxillae together; thus allowing the jaw to adapt to the occlusal forces, certainly a useful condition for the cranial architecture, which is also welcomed for osteopathic treatment.

Conclusions

In both bench and clinical testing, the Leonardo Expander has proven to be extremely

precise, assembled with care, solid and without any flexion. The Parents of the Patient activated the screw at home with particular ease and precision, thanks to the braking device. In fact this feature enabled them to hear a "click" upon each activation, and above all to not turn the screw back when removing the key, thus undoing the activation they had just completed. This is such a frequent occurrence during the activation of traditional Expanders. The whole process went ahead without any problems and with the maximum level of comfort for the young girl, thanks also to the compact

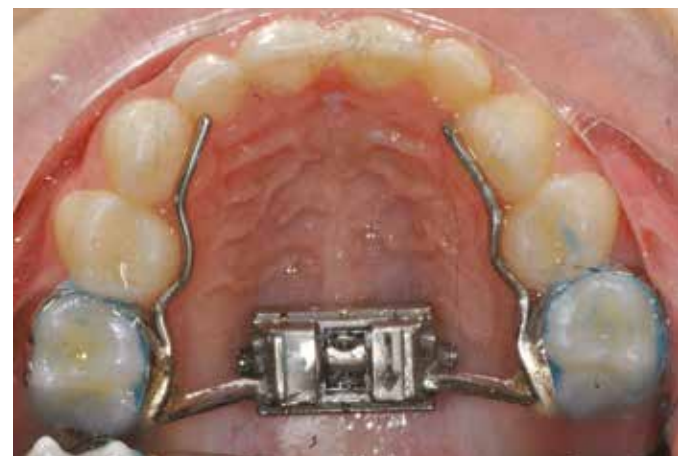

Figure 4a / 4b The expander was bonded to two bands and cemented onto the second deciduous molars

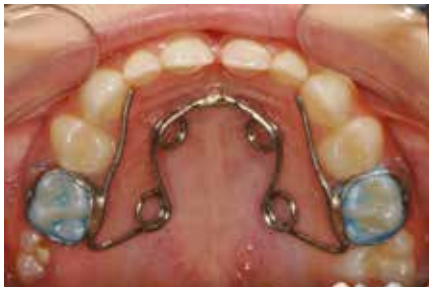

Figure 6 The expander remained blocked in the mouth for one month and was then replaced with a Quad helix

size of the Leonardo Expander; permitting effective and safe use in very young Patients. The arm and the screw of the Leonardo Expander were proven to be precise and without any flexion. The reference notches printed on the screw enabled the Clinician to check that the

activation had been performed correctly. All this resulted in a greater sense of security for both the Patient and the Therapist, as well as being appreciated as an indicator of a high level of professionalism.

References

- Font Jaume JM. Treatment in the deciduous dentition : four clinical cases. *Prog Orthod* 2006; 7(2):202-19.
- Baccetti T, Franchi L, Mc Namara JA jr, Tollaro I. Early dentofacial features in Class II malocclusion: A longitudinal study from the deciduous through the mixed dentition. *Am J Orthod Dentofac Orthop* 1997 May; 111(5): 502-9.
- Mc Namara JA. Maxillary trasverse deficiency. *Am J Orthod Dentofac Orthop* 2000; 117(5): 567-70.
- Da Silva Filho OG, Boas MC, Capelozza Fiho

L. Rapid maxillary expansion in the primary and mixed dentitions: a cephalometric evaluation. *Am J Orthod* 1991 Aug; 100(2):171-81.

- Gandolfini M, Molinari L, Mandelli G, Di Blasio A. Uso precoce del Quad-helix in ortodonzia inter-cettiva. *Mondo ortodontico* 2003;4:269-275.
- Cozza P, Pachi F, Mucedero M, Macchiarlo E. La terapia precoce del deficit di tipo trasversale. *Mondo ortodontico* 2003;4:289-300.
- C. Alicino, I. Painsi, M. Folli, G. Farronato. Asimmetria mandibolare in soggetti in fase di crescita con inversione monolaterale. *Ortognatodonzia Italiana Vol. I* 1,4-2002.
- Donald J. Timms. Rapida espansione del palato. *Scienza e tecnica dentistica edizioni internazionali Milano* 1984.
- G. Alesandri Bonetti, I. Marini, U. Capurso. *Il disgiuntore rapido del palato*. Edizioni Martina Bologna 1999

Authors

Dr. Gabriele Galassini*

Surgeon, Orthodontist

Contract Professor at Scuola di Specialità in Ortognatodonzia, University of Trieste from 2005 to 2015

Lecturer at Osteopathic College in Trieste
Dr. Gabriele Galassini Via Crociera 10 - 34074 Monfalcone (Go)

segreteria@studiogalassini.it
www.studiogalassini.it

Dr. Elena Marcuzzi**

Surgeon, Orthodontist Specialist

Dr. Paulina Natasa***

Orthodontist



Distributed by



Visit us
Level 6 Booth K-22

Technology and Innovation are our mission that's why we develop and manufacture our products cooperating with ortho specialists all over the world...
We Care.

MADE IN ITALY



www.siaorthodontics.com